

- Cesar Augusto Flores Dueñas, Soila Maribel Gaxiola Camacho, Martin Francisco Montaña Gómez, Rafael Villa Angulo, **Idalia Enríquez Verdugo**, Tomás Rentería Evangelista, José Ascención Pérez Corrales, Miguel Ángel Rodríguez Gaxiola. Canine thoracic radiographic images as an educational dataset for distance learning and research on vertebral heart score. 2021. Data in Brief. 36: (1-5). ISSN: 23523409 <https://doi.org/10.1016/j.dib.2021.107040>
CiteScore : 1.7 Impacto normalizado en origen por papel (SNIP): 2.000 . Rango de SCImago Journal (SJR): 0.122



Data Article

Canine thoracic radiographic images as an educational dataset for distance learning and research on vertebral heart score



Cesar Augusto Flores Dueñas^a, Soila Maribel Gaxiola Camacho^{a,*},
 Martin Francisco Montaña Gómez^b, Rafael Villa Angulo^c,
 Idalia Enríquez Verdugo^a, Tomás Rentería Evangelista^b,
 José Ascención Pérez Corrales^a, Miguel Ángel Rodríguez Gaxiola^a

^a Veterinary Medicine and Zootechnics School, Autonomous University of Sinaloa, Mexico

^b Veterinary Sciences Research Institute, Autonomous University of Baja California, Mexico

^c Engineering Institute, Autonomous University of Baja California, Mexico

ARTICLE INFO

Article history:

Received 11 December 2020

Revised 31 March 2021

Accepted 1 April 2021

Available online 6 April 2021

Keywords:

Radiographs

Vertebral heart score

Distance Learning

ABSTRACT

Distance learning is a rapidly spreading form of education worldwide and it plays a crucial role to provide access to millions of people in developing countries. However, the benefits of online learning extend far beyond and became increasingly popular also in medical schools, including veterinary medicine [1,2]. In these new teaching settings, high-quality, validated and easily accessible multimedia materials are of great importance, especially in specific fields, such as radiology, where graphic resources can greatly support learning [3].

The dataset presented along with this article reviews examples of 153 canine latero-lateral thoracic radiographic medical images taken and collected at the Small Animal Veterinary Teaching Hospital, Veterinary Sciences Research Institute, Autonomous University of Baja California, serves as a basis for teaching VHS calculation. Images on this dataset contain all relevant anatomical structures in the determination of VHS, which makes them optimal images for practice in calculating VHS and teaching this procedure. The number of cardi thoracic radiographic images presented here can be

* Corresponding author.

E-mail address: cflores75@uabc.edu.mx (S.M. Gaxiola Camacho).

a great support in learning the calculation of VHS, especially when combined with distance competency-based educators' support.

Acquired heart diseases in the dog are very common, clinical evidence of degenerative valvular disease is detected in approximately 30% of dogs aged 13 years and older [4]. The prevalence of Dilated Cardiomyopathy (DCM) is remarkably high in certain breeds, approximately 25% of Irish Wolfhounds, 33% of female Doberman Pinschers, and 50% of male Doberman Pinschers are diagnosed with DCM [5]. Thoracic radiography is a key component in cardiovascular evaluation, which is used to calculate the vertebral heart score (VHS). VHS measurement has been described as one of the most objective methods for assessing cardiomegaly in dogs. VHS, in addition to thorough patient history and physical examination, can be very efficient to raise clinical suspicion of underlying heart disease. The measurement is based on cardiac height and width and is normalized to overall body size by comparison to vertebral body length. In addition to the initial assessment of heart size, the VHS method is also useful for monitoring changes in heart size in response to treatment or to assess the progression of cardiomegaly over time in canine patients [6] Fig. 1. Importantly, considerable breed and individual variation exist with VHS and dogs can have values that fall outside of the normal range even without any cardiac disease. Thus, while the VHS method is a very informative tool, it should not be used as the only means of diagnosing cardiac disease in any given patient [7].

© 2021 The Authors. Published by Elsevier Inc.
This is an open access article under the CC BY-NC-ND license (<http://creativecommons.org/licenses/by-nc-nd/4.0/>)

Specifications Table

Subject	Veterinary Science and Medicine
Specific subject area	Veterinary Radiology and Imaging
Type of data	Image
How data were acquired	Universal AV Choice X-Ray System and Rayence XMARU 1417PGA-PCA 14 × 17" cassette digital detector
Data format	PNG Raw DICOM images were converted to PNG format by using a DICOM converter application included in the acquisition software
Parameters for data collection	Images are not classified Lateral thoracic radiographic images of 153 dogs from 628 available studies were selected for current material. Image selection criteria was based on inclusion of relevant anatomical structures in the determination of VHS and image quality by authors.
Description of data collection	The following parameters were used: a high peak kilovoltage (kVp) (kVp 70–80) and low milliampere-second (mA 200, ms 10–40), equivalent to 2–8 mAs. These parameters allow for latitude (long grayscale) images, which are important when evaluating the structures of the thorax.
Data source location	Small Animal Teaching Hospital Veterinary Sciences Research Institute Autonomous University of Baja California Mexico
Data accessibility	Flores Duenas, Cesar Augusto; Gaxiola Camacho, Soila Maribel; Montañó Gómez, Martín Francisco (2020), "Radiographic Dataset for VHS determination learning process", Mendeley Data, V1, doi: 10.17632/ktx4cj55pn.1 http://dx.doi.org/10.17632/ktx4cj55pn.1

Value of the Data

- This is a unique collection of a large number of radiographic images for educational purposes on VHS calculation.
- The images in the dataset help veterinary medicine Educators to build or improve the quality of distance learning.
- Researchers new to VHS measurement can also use this dataset as a reference to standardize their VHS determination procedure.
- Images can be used as a training dataset for the development of artificial intelligence-driven cardiomegaly calculation approaches.

1. Data Description

153 de-identified canine thoracic radiographic images in PNG format. The lateral beam projections extended from the cranial margin of the manubrium to the caudo-dorsal margin of the lung margin/diaphragmatic crus. The sternum of the patient was included so as not to exclude vital anatomy. The number of images collected initially was 628 and were stored in a DICOM format.

DICOM images were converted to PNG.

2. Experimental Design, Materials and Methods

Radiographic images were taken and collected at the Small Animal Veterinary Teaching Hospital, Veterinary Sciences Research Institute, Autonomous University of Baja California. The image collection and classification were performed by the authors between 2019- 2020. Over this period, all lateral thoracic radiographic studies of dogs admitted to this Veterinary Medical Teaching Hospital were considered for inclusion in this dataset. From a total of 628 studies, Latero-lateral thoracic radiographic images of 153 canine patients were selected for current material by the authors. Image selection criteria was based on inclusion of relevant anatomical structures in the determination of VHS and image quality. All dogs were mature (2 to 11 years) and ranged in weight from 5 to 35 kg. There were 83 males and 69 females. The instrument used in the radiographic image acquisition process is Universal AV Choice X-Ray System and Rayence XMARU 1417PGA-PCA 14 × 17" cassette digital detector (DR. system). In the development of radiographic studies, techniques were used in the range of the following parameters using a high peak kilovoltage (kVp 70–80) and low milliampere-second technique (mA 200, ms 10–40) equivalent to 2–8 mAs. This technique allows for latitude (long grayscale) images, which are important when evaluating the structures of the thorax. For a right and left lateral image, patients were positioned on the table with the dependent side down. Relevant anatomical structures in the determination of VHS were included. The laterals beam projections extended from the cranial margin of the manubrium to the caudo-dorsal margin of the lung margin/diaphragmatic crus. The sternum of the patient was included so as not to exclude vital anatomy. The number of images collected initially was 628 and were stored in a DICOM format.

DICOM images were converted to PNG format by using a DICOM converter application included in the acquisition software. After performing classification and preprocessing, the number of images included in the final dataset was reduced to 153 representative images. All images were cropped to different sizes to remove unused and unimportant boundaries from the images. The original VHS measurement was not included in the image because it may affect the output results of the training process. Fig. 2 shows a representative example of the original scanned images Fig. 1.

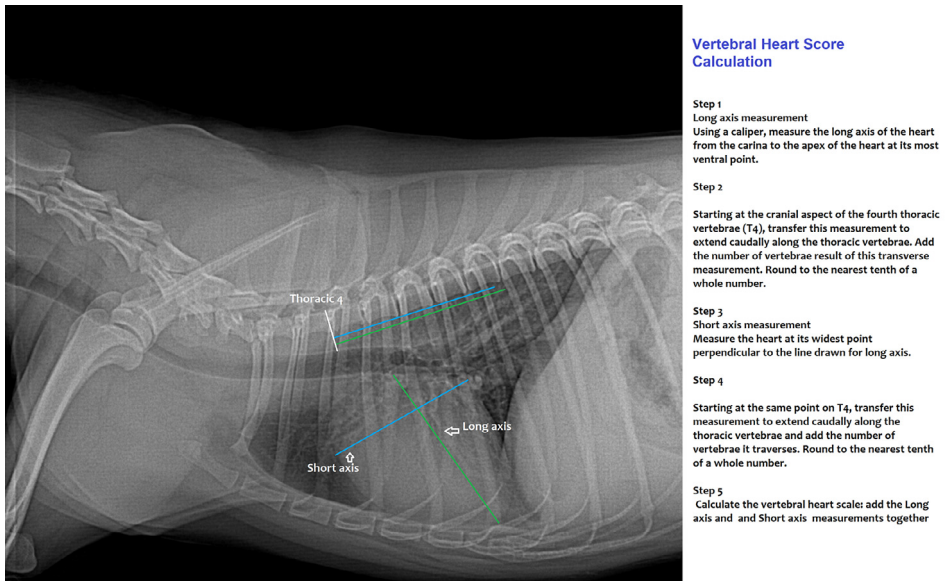


Fig. 1. Vertebral Heart Score (VHS) calculation guide on a 5 years, female mixed breed canine patient. Instructions based on technique described on (6) Buchanan JW, Bucheler J. Vertebral scale system to measure canine heart size in radiographs. J Am Vet Med Assoc. 1995;206(2):194–199.

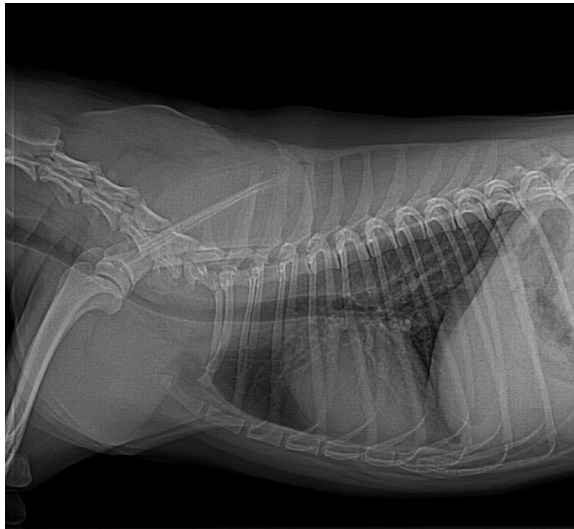


Fig. 2. L-L Thoracic radiograph sample of the dataset.

Ethics Statement

This work includes canine thoracic X-ray images of patients collected from the Small Animal Teaching Hospital, Veterinary Sciences Research Institute, Autonomous University of Baja California, Mexicali, Mexico. The radiographic images are de-identified. The image acquisition protocol was approved by the ethics committee of the Veterinary Sciences Research Institute of

the Autonomous University of Baja California (Ethics approval number 087 IICV-UABC) All procedures comply with the [ARRIVE guidelines](#) and were being carried out in accordance with the U.K. Animals (Scientific Procedures) Act, 1986 and associated guidelines, [EU Directive 2010/63/EU for animal experiments](#), or the National Institutes of Health guide for the care and use of laboratory animals (NIH Publications No. 8023, revised 1978).

Credit Author Statement

Cesar Augusto Flores Dueñas: Conceptualization, Methodology, Image acquisition; **Soila Maribel Gaxiola Camacho, Martin Francisco Montaña Gómez, Rafael Villa Angulo:** Writing, Original draft preparation; **Idalia Enríquez Verdugo, Tomás Rentería Evangelista:** Writing- Reviewing and Editing; **José Ascención Pérez Corrales, Miguel Ángel Rodríguez Gaxiola:** Visualization, Investigation.

Declaration of Competing Interest

The authors declare that they have no known competing financial interests or personal relationships which have or could be perceived to have influenced the work reported in this article.

Acknowledgments

Our gratitude to the Veterinary Sciences Research Institute, Autonomous University of Baja California, for the support and facilities for the realization of this project.

References

- [1] I. Masic, E-learning as new method of medical education, *Acta Inform. Med.* 16 (2) (2008) 102–117 PMID: 24109154; PMCID: PMC3789161, doi:10.5455/aim.2008.16.102-117.
- [2] N.A. Al Saiyd, I.A. Al Sayed, Multimedia distance E-learning system for higher education students, in: V. Snasel, J. Platos, E. El-Qawasmeh (Eds.), *Digital Information Processing and Communications ICDIPC 2011 eds*, Springer, Berlin, Heidelberg, 2011 Communications in computer and information science Vol 188.
- [3] C.P. Ober, Examination outcomes following use of card games for learning radiographic image quality in veterinary medicine, *J. Vet. Med. Educ.* 45 (1) (2018) 140–144.
- [4] eds: J.A. Abbott, Chapter 6-acquired valvular disease, in: P.Tilley Larry, W.K.Smith Francis, A.Oyama Mark, M.Sleeper Meg (Eds.), *Manual of Canine and Feline Cardiology*, 4th ed, W.B. Saunders, 2008, pp. 110–138.
- [5] Editor(s): A. Oyama M, Chapter 7-canine cardiomyopathy, in: P.Tilley Larry, W.K.Smith Francis, A.Oyama Mark, M.Sleeper Meg (Eds.), *Manual of Canine and Feline Cardiology*, 4th Edition, W.B. Saunders, 2008, pp. 139–150. Pages.
- [6] J. Buchanan, J.B. Bücheler, Vertebral Scale system to measure canine heart size in radiographs, *J. Am. Vet. Med. Assoc.* 206 (1995) 194–199.
- [7] S. Fox-Alvarez, A. Estrada, Vertebral heart scale, *Clin. Brief* (2016) 49–53.