



## Novel *TINF2* gene mutation in dyskeratosis congenita with extremely short telomeres: A case report

Verónica Judith Picos-Cárdenas, Saúl Armando Beltrán-Ontiveros, José Alfonso Cruz-Ramos, José Alfredo Contreras-Gutiérrez, Eliakym Arámbula-Meraz, Carla Angulo-Rojo, Alma Marlene Guadrón-Llanos, Emir Adolfo Leal-León, Dora María Cedano-Prieto, Juan Pablo Meza-Espinoza

**Specialty type:** Dermatology

**Provenance and peer review:**

Unsolicited article; Externally peer reviewed.

**Peer-review model:** Single blind

**Peer-review report's scientific quality classification**

Grade A (Excellent): 0

Grade B (Very good): B

Grade C (Good): C, C

Grade D (Fair): 0

Grade E (Poor): 0

**P-Reviewer:** Ishida T, Japan;  
Vyshka G, Albania

**Received:** September 13, 2022

**Peer-review started:** September 13, 2022

**First decision:** September 26, 2022

**Revised:** October 13, 2022

**Accepted:** October 20, 2022

**Article in press:** October 20, 2022

**Published online:** November 26, 2022



**Verónica Judith Picos-Cárdenas**, Laboratorio de Genética, Facultad de Medicina, Universidad Autónoma de Sinaloa, Culiacán 80018, Sinaloa, Mexico

**Saúl Armando Beltrán-Ontiveros**, Centro de Investigación y Docencia en Ciencias de la Salud, Hospital Civil de Culiacán, Universidad Autónoma de Sinaloa, Culiacán 80030, Sinaloa, Mexico

**José Alfonso Cruz-Ramos**, Departamento de Clínicas Médicas, Centro Universitario de Ciencias de la Salud, Universidad de Guadalajara, Guadalajara 44340, Jalisco, Mexico

**José Alfredo Contreras-Gutiérrez**, Facultad de Medicina, Universidad Autónoma de Sinaloa, Culiacán 80018, Sinaloa, Mexico

**Eliakym Arámbula-Meraz, Emir Adolfo Leal-León, Dora María Cedano-Prieto**, Laboratorio de Genética y Biología Molecular, Facultad de Ciencias Químico-Biológicas, Universidad Autónoma de Sinaloa, Culiacán 80010, Sinaloa, Mexico

**Carla Angulo-Rojo**, Laboratorio de Neurociencias, Facultad de Medicina, Universidad Autónoma de Sinaloa, Culiacán 80018, Sinaloa, Mexico

**Alma Marlene Guadrón-Llanos**, Laboratorio de Diabetes y Comorbilidades, Facultad de Medicina, Universidad Autónoma de Sinaloa, Culiacán 80018, Sinaloa, Mexico

**Juan Pablo Meza-Espinoza**, Facultad de Medicina, Universidad Autónoma de Tamaulipas, Matamoros 87349, Tamaulipas, Mexico

**Corresponding author:** Juan Pablo Meza-Espinoza, PhD, Researcher, Facultad de Medicina, Universidad Autónoma de Tamaulipas, Sendero Nacional km 3, Matamoros 87349, Tamaulipas, Mexico. [sirol1073@yahoo.com.mx](mailto:sirol1073@yahoo.com.mx)

### Abstract

#### BACKGROUND

Dyskeratosis congenita is a rare disease characterized by bone marrow failure and a clinical triad of oral leukoplakia, nail dystrophy, and abnormal skin pigmentation. The genetics of dyskeratosis congenita include mutations in genes involved in telomere maintenance, including *TINF2*.

## CASE SUMMARY

Here, we report a female patient who presented thrombocytopenia, anemia, reticulate hyperpigmentation, dystrophy in fingernails and toenails, and leukoplakia on the tongue. A histopathological study of the skin showed dyskeratocytes; however, a bone marrow biopsy revealed normal cell morphology. The patient was diagnosed with dyskeratosis congenita, but her family history did not reveal significant antecedents. Whole-exome sequencing showed a novel heterozygous punctual mutation in exon 6 from the *TINF2* gene, namely, NM\_001099274.1:-c.854delp.(Val285Alafs\*32). An analysis of telomere length showed short telomeres relative to the patient's age.

## CONCLUSION

The disease in this patient was caused by a germline novel mutation of *TINF2* in one of her parents.

**Key Words:** Dyskeratosis congenita; *TINF2*; Germline mutation; Novel mutation; Short telomeres; Case report

©The Author(s) 2022. Published by Baishideng Publishing Group Inc. All rights reserved.

**Core Tip:** Dyskeratosis congenita, characterized by a clinical triad of oral leukoplakia, nail dystrophy, and abnormal skin pigmentation, is a rare disease caused by mutations in genes governing telomere maintenance, including *TINF2*. We performed whole-exome sequencing in a female pediatric patient who presented with dyskeratosis congenita, and subsequently, a novel heterozygous mutation in exon 6 of the *TINF2* gene was detected: NM\_001099274.1:c.854delp.(Val285Alafs\*32). An analysis of telomere length demonstrated short telomeres relative to the girl's age. Patients with *TINF2* mutations have more severe disease, so their detection is necessary to provide timely treatment.

**Citation:** Picos-Cárdenas VJ, Beltrán-Ontiveros SA, Cruz-Ramos JA, Contreras-Gutiérrez JA, Arámbula-Meraz E, Angulo-Rojó C, Guadrón-Llanos AM, Leal-León EA, Cedano-Prieto DM, Meza-Espinoza JP. Novel *TINF2* gene mutation in dyskeratosis congenita with extremely short telomeres: A case report. *World J Clin Cases* 2022; 10(33): 12440-12446

**URL:** <https://www.wjgnet.com/2307-8960/full/v10/i33/12440.htm>

**DOI:** <https://dx.doi.org/10.12998/wjcc.v10.i33.12440>

## INTRODUCTION

Dyskeratosis congenita is a rare genetic disease whose prevalence in the general population has been estimated at nearly 1/1000000[1]. This disorder is characterized by bone marrow failure and a typical clinical triad comprised of oral leukoplakia, nail dystrophy, and abnormal skin pigmentation. The risk of aplastic anemia, myelodysplastic syndrome, and leukemia is elevated in patients with this condition [2,3]. Other clinical findings in dyskeratosis congenita include pulmonary fibrosis, liver cirrhosis, and premature hair graying[4]. The genetics of dyskeratosis congenita involve mutations in genes that govern the maintenance of telomeres; therefore, this disorder is marked, molecularly, by a progressive shortening of telomeres[5,6]. The genes associated with dyskeratosis congenita are *DKC1*, *TERC*, *TERT*, *TINF2*, *RTEL1*, *PARN*, *ACD*, *NOP10*, *NHP2*, *TERT*, *USB1*, and *WRAP53*[2,3,7] (Table 1). Pathogenic variants in any of these genes have been identified in most individuals who meet diagnostic criteria for dyskeratosis congenita[3]. Because of this locus heterogeneity, there is a wide clinical variation among patients with this syndrome[8]. Here, we report the case of a girl with dyskeratosis congenita who carries a previously undescribed germline mutation in the *TINF2* gene and an extremely short telomere length.

## CASE PRESENTATION

### Chief complaints

A 13-year-old Mexican female patient, height 151.0 cm and weight 48.0 kg, was found to have thrombocytopenia, anemia, abnormal skin pigmentation, dystrophic nails, and leukoplakia on the tongue.

**Table 1 Genetic spectrum of dyskeratosis congenita[1,3]**

Gene	Chromosome	Inheritance pattern	Frequency, %	Main mutation types
<i>DKC1</i>	Xq28	XLR	Approximately 25	Missense
<i>TINF2</i>	14q12	AD	Approximately 12	Missense
<i>TERC</i>	3q26	AD	Approximately 5	Point and deletions
<i>TERT</i>	5p15	AD, AR	Approximately 5	Missense
<i>USB1</i>	16q21	AR	Approximately 2	Frameshift and nonsense
<i>RTEL1</i>	20q13	AR, AD	Approximately 2	Missense
<i>CTC1</i>	17p13	AR	Approximately 1	Missense and frameshift
<i>NHP2</i>	5q35	AR	< 1	Missense
<i>NOP10</i>	15q14	AR	< 1	Missense
<i>WRAP53</i>	17p13	AR	< 1	Missense
<i>ACD</i>	16q22	AD, AR	< 1	Missense and frameshift
<i>PARN</i>	16p13	AR, AD	< 1	Frameshift

XLR: X-linked recessive; AD: Autosomal dominant; AR: Autosomal recessive.

### History of present illness

The patient was the product of the second pregnancy of healthy nonconsanguineous parents (both parents were 31 years old at the time of birth). At the age of 5 years, she was detected to have thrombocytopenia and anemia (platelets 26000/mm<sup>3</sup> and hemoglobin 9.0 g/dL); peripheral blood cell smears showed normal morphology and no evidence of blasts. She was thought to have primary immune thrombocytopenia. Prednisone (1 mg/kg/d) was administered as therapy for 21 d. After the administration of prednisone, platelet and hemoglobin counts have fluctuated from 32000/mm<sup>3</sup> to 110000/mm<sup>3</sup> and 9.5 g/dL to 11.7 g/dL, respectively.

When the patient was 9 years old, she was suspected to have systemic lupus erythematosus and mixed connective tissue disease due to her nail dystrophy and neck pigmentation abnormalities, but an antinuclear antibody test was negative. Methotrexate was administered as prophylaxis regardless. Around this time, an esophagogram was performed due to her difficulty swallowing since childhood; this revealed esophageal stenosis requiring two endoscopies for dilation. At the age of 11, dyskeratosis congenita was suspected due to the progression of reticulate pigmentation to the entire upper trunk, the presence of leukoplakia on the tongue, and the evolution of fingernails and toenails dystrophy; a molecular study was subsequently performed.

### History of past illness

The patient had no history of other significant diseases.

### Personal and family history

The patient had a healthy older brother, and family history did not indicate any significant morbidities.

### Physical examination

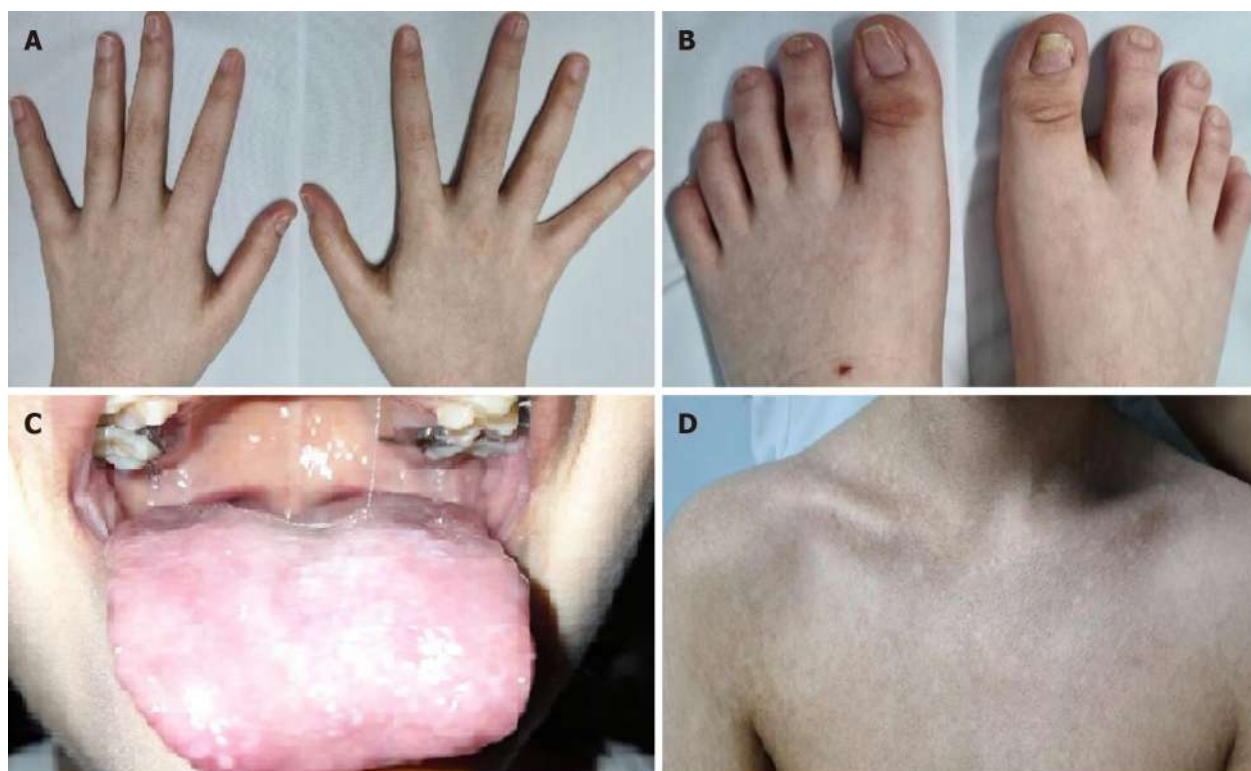
At the age of 6, the patient presented with microcephaly, reticulate pigmentation in the neck, neckline, and axillae, dystrophic nails on hands and feet (Figure 1A and B), and lacrimal obstruction in the right eye. At the age of 11, she showed leukoplakia on the tongue (Figure 1C), and her reticulate pigmentation progressed to the entire upper trunk (Figure 1D).

### Laboratory examinations

A histopathological study of the skin showed dyskeratocytes (Figure 2). Although previous peripheral blood smears showed normal leukocyte counts and the absence of blasts throughout the disease, a bone marrow biopsy was performed, which revealed normal cellularity.

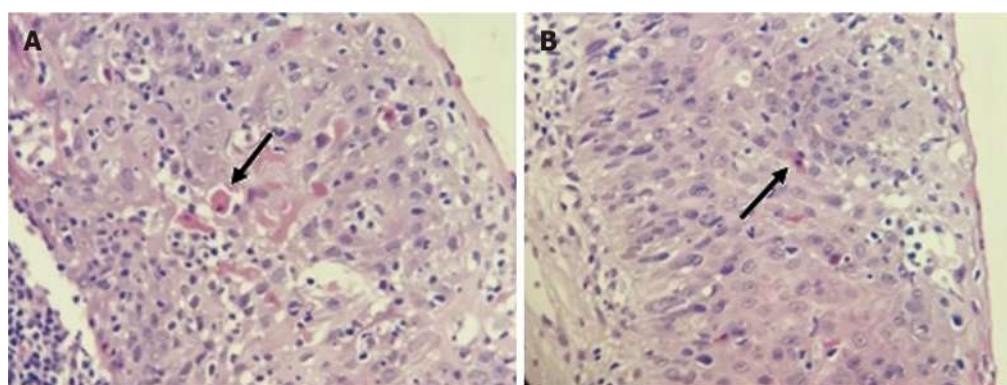
### Whole-exome sequencing

Whole-exome sequencing analysis was performed according to the manufacturer's protocol. DNA was enzymatically fragmented and hybridized with CentoXome™ (CENTOGENE, Rostock, Germany). Libraries were generated with Illumina-compatible adapters and sequenced on the Illumina platform (Illumina, Inc., San Diego, CA, United States). Sequenced readings were aligned to the hg19 version of



DOI: 10.12998/wjcc.v10.i33.12440 Copyright ©The Author(s) 2022.

**Figure 1 Clinical findings in the patient.** A: Dystrophic fingernails; B: Dystrophic toenails; C: White patches on the tongue representing leukoplakia; D: Upper trunk showing reticulate skin pigmentation.



DOI: 10.12998/wjcc.v10.i33.12440 Copyright ©The Author(s) 2022.

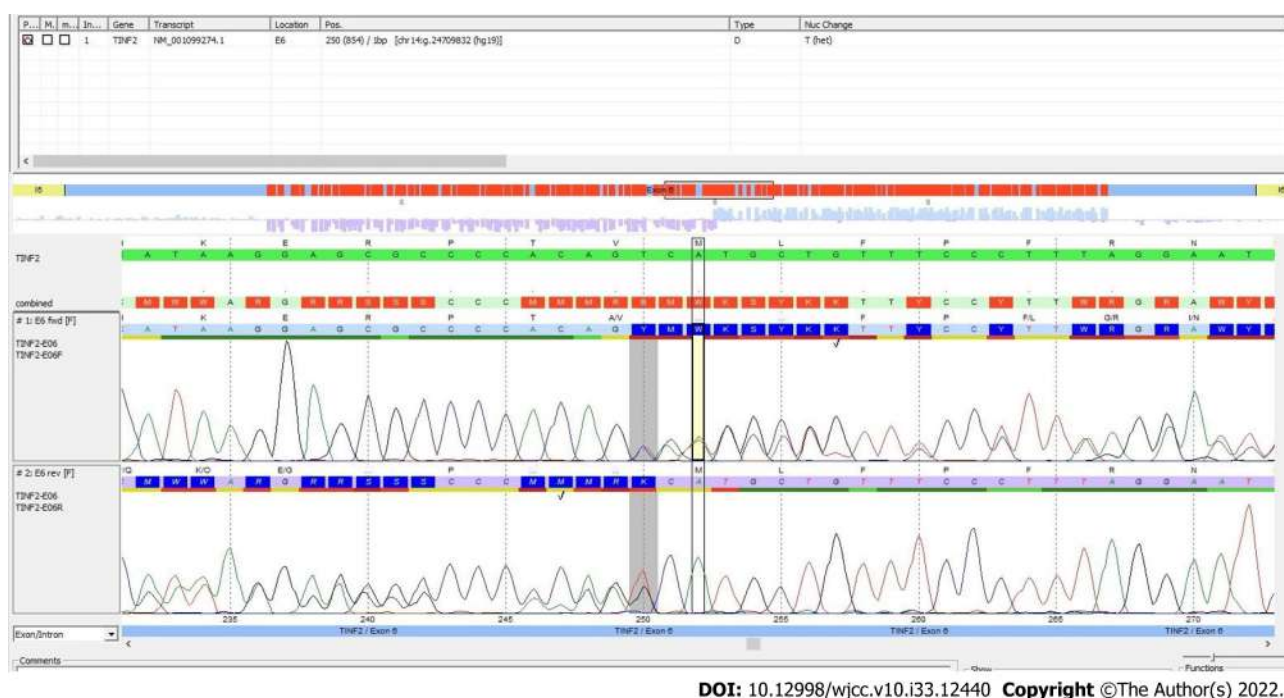
**Figure 2 Histopathological study.** A and B: Skin biopsy images showing dyskeratocytes. The arrows point to these abnormal cells.

the human genome (Genome Reference Consortium GRCh37) using validated software (Rostock, Germany). All variants reported in the *Human Gene Mutation Database* (HGMD®), ClinVar, and CentoMD, as well as those in which the frequency of the least common allele was less than 1% in the Single Nucleotide Polymorphism database (dbSNP) and the Genome Aggregation Database (gnomAD) were considered. After analysis, a novel mutation, Chr14(GRCh37):g.24709832del NM\_001099274.1:c.854delp.(Val285Alafs\*32), was identified in exon 6 of the *TINF2* gene. This mutation was verified by Sanger sequencing. Bidirectional sequencing and comparison to the coding sequence of *TINF2* was performed (Figure 3). The reference sequence was NM\_001099274.1.

### Telomere analysis

To assess telomere length, genomic DNA was extracted from peripheral blood leukocytes using the Flexigene DNA kit (QIAGEN, Hilden, Germany) and qPCR was performed using the Absolute Human Telomere Length and Mitochondrial DNA Copy Number Dual Quantification qPCR kit (ScienCell Research Laboratories, San Diego, CA, United States) on a CFX96 Touch Real-Time PCR Detection System (Bio-Rad, Hercules, CA, United States) according to the supplier's recommendations. The





**Figure 3 Sequencing study.** Plot showing the identification of the mutation in the *TINF2* gene (deletion of the T in the position 250; shaded area). Courtesy of Centogene AG, Rostock, Germany.

analysis showed an absolute telomere length of  $2.80 \pm 0.09$  kb.

## FINAL DIAGNOSIS

Based on clinical features and molecular analysis, the patient was diagnosed with dyskeratosis congenita.

## TREATMENT

Prednisone (1 mg/kg/d) is administered as therapy for 21 d, whenever platelet count drops by nearly  $30000/\text{mm}^3$ .

## OUTCOME AND FOLLOW-UP

Hopefully, the patient has had a favorable evolution, as she has not developed aplastic anemia or bone marrow failure, although she is currently off medication.

## DISCUSSION

Dyskeratosis congenita is caused more than 99% of the time by a germline mutation in one of the parents[9], as was the case of our patient, who presented with the typical triad of this disease: Dystrophy in fingernails and toenails, leukokeratosis plaques on the tongue, and reticulate skin pigmentation. Mutations in the *TINF2* gene (which encodes the TIN2 protein, a component of the shelterin telomere protection complex)[2] represent the second most common cause of dyskeratosis congenita, accounting for approximately 12% of the cases, only after mutations in the *DKC1* gene (approximately 25%)[1]. It is well known that patients with a mutation in the *TINF2* gene have a more severe course and a higher risk of developing aplastic anemia before the age of 10 years[6]. To date, there are more than 200 punctual variations in the *TINF2* gene recorded in the ClinVar database. Most of them result in missense mutations, eight in nonsense, and almost twenty are frameshift mutations (Table 2), although some are associated with Revesz syndrome, a more severe variant of dyskeratosis congenita. Most pathogenic mutations occur in exon 6, principally between codons 280 and 288[10]. The

**Table 2** Frameshift mutations in *TINF2* causing dyskeratosis congenita[10]

Location (GRCh37)	Mutation	Protein change
Chr14:24709067	NM_001099274.3(TINF2):c.1292del (p.Pro431fs)	P431fs
Chr14:24709132	NM_001099274.3(TINF2):c.1227del (p.Leu410fs)	L410fs
Chr14:24709288-24709289	NM_001099274.3(TINF2):c.1202dup (p.Asn401fs)	N401fs
Chr14:24709507-24709508	NM_001099274.3(TINF2):c.1090dup (p.Leu364fs)	L364fs
Chr14:24709627-24709628	NM_001099274.3(TINF2):c.1058dup (p.Glu354fs)	E354fs
Chr14:24709676	NM_001099274.3(TINF2):c.1010del (p.Gly337fs)	G337fs
Chr14:24709794	NM_001099274.3(TINF2):c.892del (p.Gln298fs)	Q298fs
Chr14:24709836-24709837	NM_001099274.3(TINF2):c.849dup (p.Thr284fs)	T284fs
Chr14:24709860	NM_001099274.3(TINF2):c.826del (p.Arg276fs)	R276fs
Chr14:24710080	NM_001099274.3(TINF2):c.606del (p.Glu202fs)	E202fs
Chr14:24710937-24710938	NM_001099274.3(TINF2):c.342_343del (p.Phe114fs)	F114fs
Chr14:24711135-24711136	NM_001099274.3(TINF2):c.257_258del (p.His86fs)	H86fs
Chr14:24711394-24711395	NM_001099274.3(TINF2):c.144_145insTT (p.Val49fs)	V49fs

mutation detected in this patient was a deletion of a nucleotide (frameshift), which also occurred in exon 6, codon 285, and caused an amino acid change at position 285 and a stop codon 31 amino acids later.

While telomere shortening is a molecular feature of dyskeratosis congenita[5], this is dramatic in patients with *TINF2* mutations[11], as their telomere lengths are significantly shorter than those of patients with *DKC1* mutations[6]. Our case showed an absolute telomere length of  $2.80 \pm 0.09$  kb, which is considered very short relative to the patient's age. As a reference, a study performed on healthy young women aged 18 to 30 years showed an absolute telomere length of  $4.59 \pm 0.24$  kb[12]. *TINF2* is important for telomere protection, and *TINF2* deficiency increases the risk of telomeric DNA damage and consequent telomere shortening[13-15]. Short telomeres are known to cause premature aging and increase the risk of developing cancer[16]. Accordingly, patients with dyskeratosis congenita have a higher risk of developing bone marrow failure, acute leukemia, myelodysplastic syndrome, and squamous cell carcinoma of the head and neck[3]. However, despite her extremely short telomere length, our patient has had a favorable evolution, as she has not developed aplastic anemia or bone marrow failure, although she is currently off medication.

## CONCLUSION

Since patients with mutations in the *TINF2* gene have a more severe course and a higher risk of developing aplastic anemia[6], it is important to detect patients with such mutations to follow them more frequently, mainly through blood cytometry, and, if necessary, to provide some treatment, as has been done in this patient. In the meantime, she and her parents are hoping for an orphan or experimental drug that will impede the progression of the disease.

The strength of this case report is that it was approached with a clinical, genetic, and pathological focus. The main limitation is that it is a single case.

## ACKNOWLEDGEMENTS

We thank the proband and her parents for their collaboration and support for the publication of this case. We also thank the biomedicine and genomic biotechnology students, Liliana Itzel Patrón Baro (fellowship PROF-API-UAS-2022, Pro\_A3\_031) and Lucero García Hernández, respectively, for the technical and samples collection support. Special thanks to Centogene AG, Germany for its support for the whole-exome sequencing analysis.

## FOOTNOTES

**Author contributions:** Picos-Cárdenas VJ conceptualization, data collection, and manuscript preparation; Beltrán-

Ontiveros SA, Contreras-Gutiérrez JA, Arámbula-Meraz E, and Angulo-Rojo C performed clinical examination and data analysis; Cruz-Ramos JA telomere study and critical review; Guadrón-Llanos AM, Leal-León EA, Cedano-Prieto DM collection of samples and interpretation of molecular studies; Meza-Espinoza JP supervision, drafting, reviewing, and editing. All the authors approved the final version of the manuscript.

**Informed consent statement:** Written consent was obtained from the patient's parents for the publication of this case and the accompanying images.

**Conflict-of-interest statement:** All the authors indicated no conflicts of interest.

**CARE Checklist (2016) statement:** The authors have read the CARE Checklist (2016). The manuscript was prepared and revised according to the CARE Checklist (2016).

**Open-Access:** This article is an open-access article that was selected by an in-house editor and fully peer-reviewed by external reviewers. It is distributed in accordance with the Creative Commons Attribution NonCommercial (CC BY-NC 4.0) license, which permits others to distribute, remix, adapt, build upon this work non-commercially, and license their derivative works on different terms, provided the original work is properly cited and the use is non-commercial. See: <https://creativecommons.org/licenses/by-nc/4.0/>

**Country/Territory of origin:** Mexico

**ORCID number:** Verónica Judith Picos-Cárdenas 0000-0002-4320-9619; Saúl Armando Beltrán-Ontiveros 0000-0002-8411-0957; José Alfonso Cruz-Ramos 0000-0002-5791-612X; José Alfredo Contreras-Gutiérrez 0000-0003-3774-1278; Eliakym Arámbula-Meraz 0000-0003-1026-7430; Carla Angulo-Rojo 0000-0002-5097-2444; Alma Marlene Guadrón-Llanos 0000-0003-4782-6398; Emir Adolfo Leal-León 0000-0001-9927-5917; Dora María Cedano-Prieto 0000-0002-4204-2175; Juan Pablo Meza-Espinoza 0000-0003-2621-7649.

**S-Editor:** Liu JH

**L-Editor:** A

**P-Editor:** Liu JH

## REFERENCES

- Dokal I, Vulliamy T, Mason P, Bessler M. Clinical utility gene card for: Dyskeratosis congenita - update 2015. *Eur J Hum Genet* 2015; **23** [PMID: 25182133 DOI: 10.1038/ejhg.2014.170]
- Savage SA, Giri N, Baerlocher GM, Orr N, Lansdorp PM, Alter BP. TINF2, a component of the shelterin telomere protection complex, is mutated in dyskeratosis congenita. *Am J Hum Genet* 2008; **82**: 501-509 [PMID: 18252230 DOI: 10.1016/j.ajhg.2007.10.004]
- Savage SA, Niewisch MR. Dyskeratosis Congenita and Related Telomere Biology Disorders. 2009 Nov 12. In: GeneReviews® [Internet]. Seattle (WA): University of Washington, Seattle; 1993 [PMID: 20301779]
- Wang P, Xu Z. Pulmonary fibrosis in dyskeratosis congenita: a case report with a PRISMA-compliant systematic review. *BMC Pulm Med* 2021; **21**: 279 [PMID: 34479523 DOI: 10.1186/s12890-021-01645-w]
- Nelson ND, Bertuch AA. Dyskeratosis congenita as a disorder of telomere maintenance. *Mutat Res* 2012; **730**: 43-51 [PMID: 21745483 DOI: 10.1016/j.mrfmmm.2011.06.008]
- Walne AJ, Vulliamy T, Beswick R, Kirwan M, Dokal I. TINF2 mutations result in very short telomeres: analysis of a large cohort of patients with dyskeratosis congenita and related bone marrow failure syndromes. *Blood* 2008; **112**: 3594-3600 [PMID: 18669893 DOI: 10.1182/blood-2008-05-153445]
- Dyskeratosis congenita, autosomal dominant 1 in: Online Mendelian Inheritance in Man. Available from: <https://omim.org/entry/127550>
- Barbaro PM, Ziegler DS, Reddel RR. The wide-ranging clinical implications of the short telomere syndromes. *Intern Med J* 2016; **46**: 393-403 [PMID: 26247919 DOI: 10.1111/imj.12868]
- AlSabbagh MM. Dyskeratosis congenita: a literature review. *J Dtsch Dermatol Ges* 2020; **18**: 943-967 [PMID: 32930426 DOI: 10.1111/ddg.14268]
- TINF2 gene in: ClinVar. Available from: <https://www.ncbi.nlm.nih.gov/clinvar/?term=TINF2%5Bgene%5D&redir=gene>
- Frescas D, de Lange T. A TIN2 dyskeratosis congenita mutation causes telomerase-independent telomere shortening in mice. *Genes Dev* 2014; **28**: 153-166 [PMID: 24449270 DOI: 10.1101/gad.233395.113]
- Hagman M, Frisrup B, Michelin R, Krustup P, Asghar M. Football and team handball training postpone cellular aging in women. *Sci Rep* 2021; **11**: 11733 [PMID: 34083635 DOI: 10.1038/s41598-021-91255-7]
- Kim SH, Beausejour C, Davalos AR, Kaminker P, Heo SJ, Campisi J. TIN2 mediates functions of TRF2 at human telomeres. *J Biol Chem* 2004; **279**: 43799-43804 [PMID: 15292264 DOI: 10.1074/jbc.M408650200]
- Lansdorp PM. Telomeres, aging, and cancer: the big picture. *Blood* 2022; **139**: 813-821 [PMID: 35142846 DOI: 10.1182/blood.2021014299]
- Sasa GS, Ribes-Zamora A, Nelson ND, Bertuch AA. Three novel truncating TINF2 mutations causing severe dyskeratosis congenita in early childhood. *Clin Genet* 2012; **81**: 470-478 [PMID: 21477109 DOI: 10.1111/j.1399-0004.2011.01658.x]
- Takai KK, Kibe T, Donigian JR, Frescas D, de Lange T. Telomere protection by TPP1/POT1 requires tethering to TIN2. *Mol Cell* 2011; **44**: 647-659 [PMID: 22099311 DOI: 10.1016/j.molcel.2011.08.043]



Published by **Baishideng Publishing Group Inc**  
7041 Koll Center Parkway, Suite 160, Pleasanton, CA 94566, USA

**Telephone:** +1-925-3991568

**E-mail:** [bpgoffice@wjgnet.com](mailto:bpgoffice@wjgnet.com)

**Help Desk:** <https://www.f6publishing.com/helpdesk>

<https://www.wjgnet.com>

